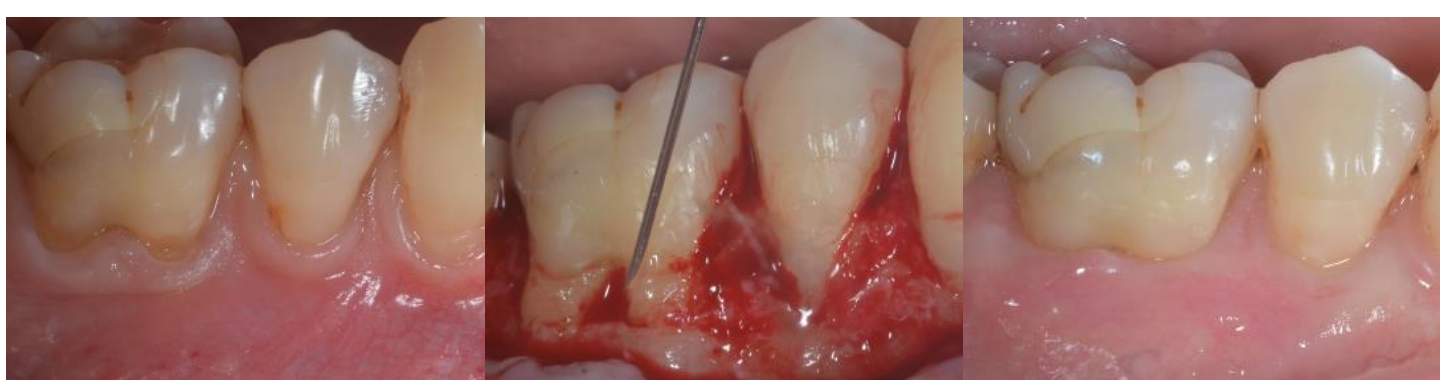
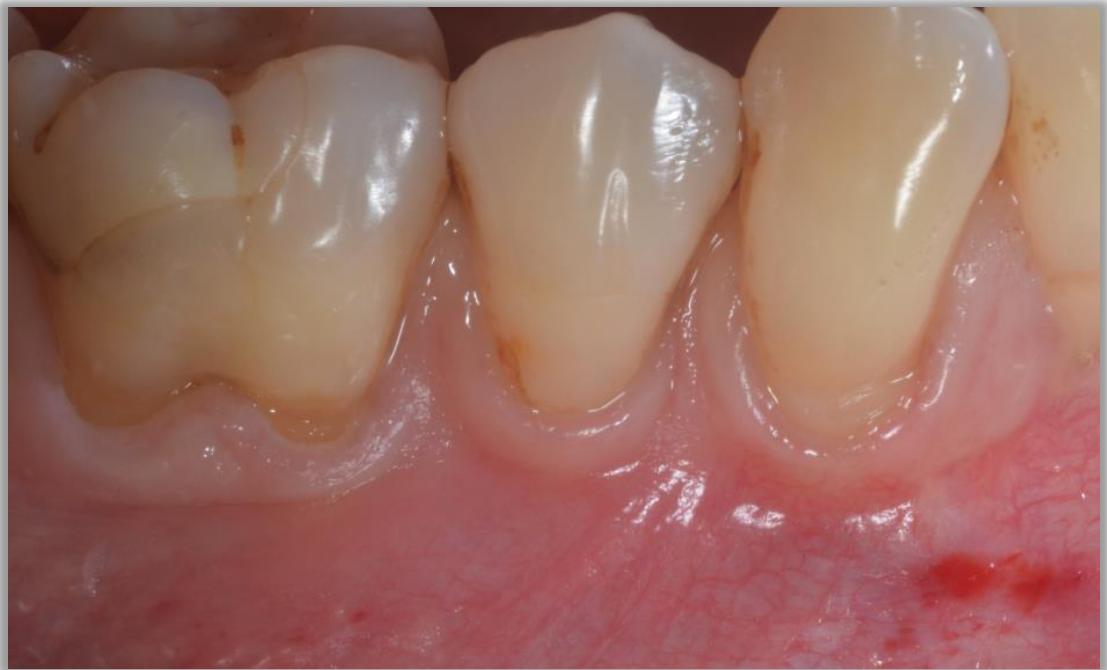

Mandibular Gingival Recession with Furcation Involvement Treated with Cross-linked Hyaluronic Acid

Clinical case and insights
by Dr Sofia Aroca



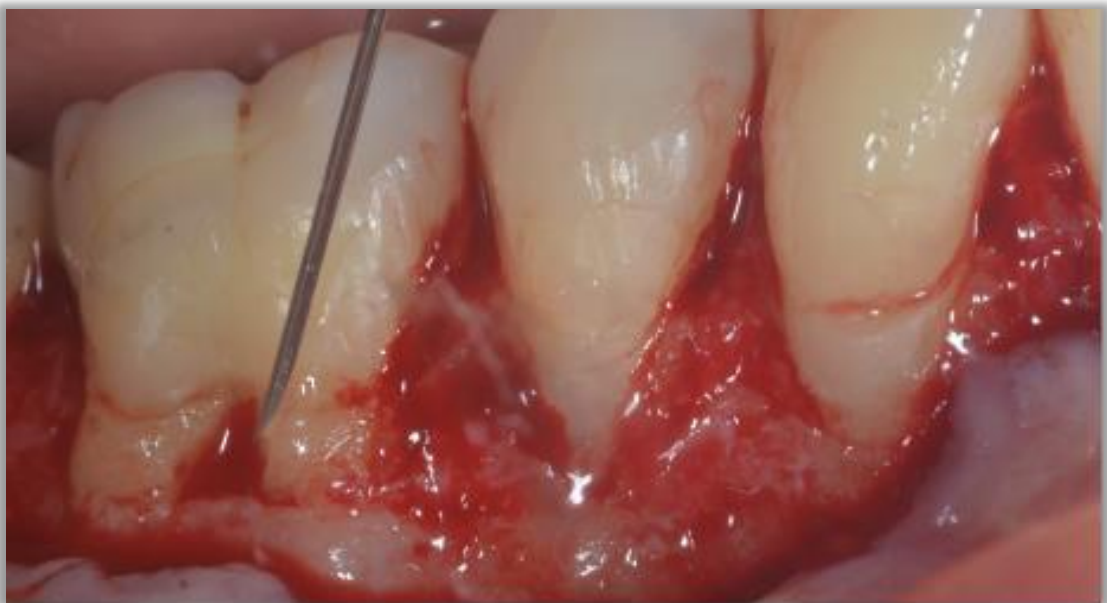

Diagnosis

Multiple recession type 1 (RT1) recession defects on teeth 43, 44 and 46 with class I furcation involvement on tooth 46: Gingival recession defect with a thin gingival profile on tooth 43.

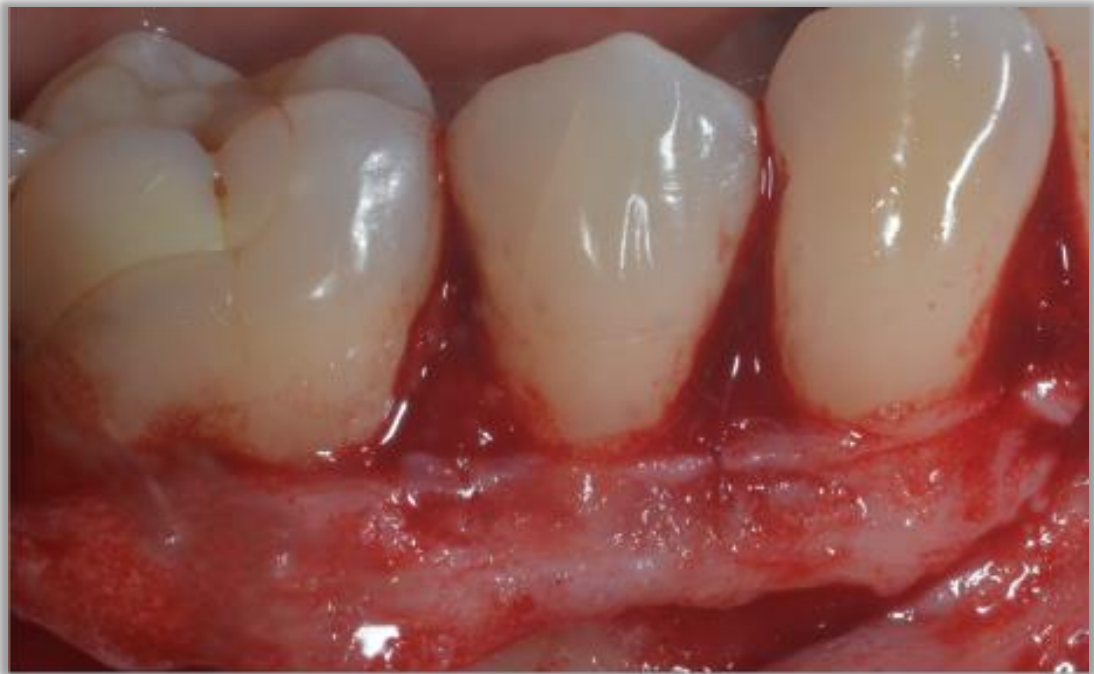Expected challenge

Complete root coverage and treatment of the class I furcation defect.



Surgery

Split-Full-Split flap design (technique established by Zucchelli & De Sanctis, 2000) and application of cross-linked hyaluronic acid (Hyadent BG). Hyadent BG mixes well with blood and stabilizes the blood clot on site, which is essential for its clinical efficacy.

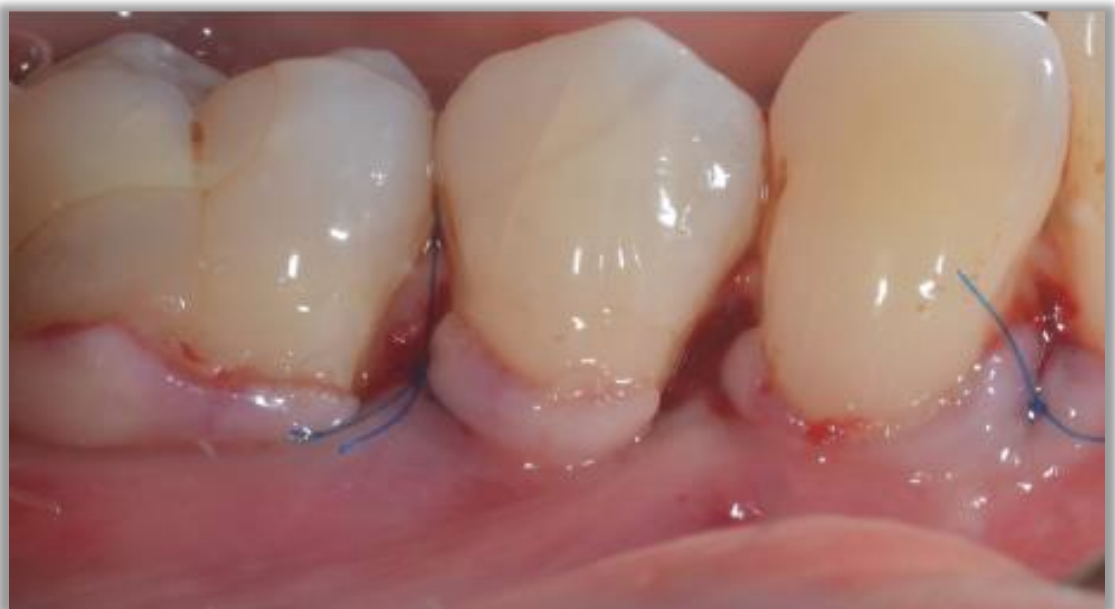

Surgery

The connective tissue graft is sutured and stabilized. A challenge when applying the graft is maintaining the regenerative biomaterial in situ.

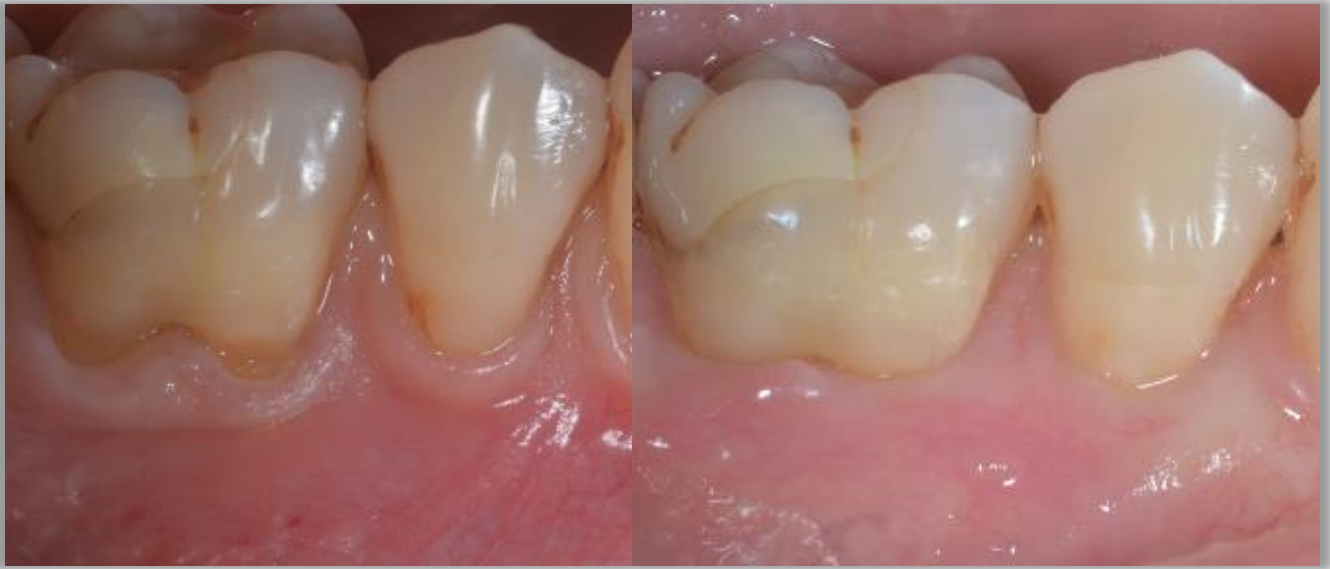Tip

Secure the graft with internal resorbable sutures



Surgery

The wound is closed by coronally advancing the flap margin (without tension) by at least 1,5 mm c to the cemento enamel junction (CEJ) with separated suspended sutures.



Outcome

Before , 1 year and 3 years (below) after the operation: The recession remains well covered with healthy soft tissue and an aesthetic result with minimal scars.

In this case, Hyadent BG was applied for its anti-inflammatory and bacteriostatic effects.

